Disorders development of teeth

LAB 13

Box 2-5 *Developmental Alterations of Teeth*

NUMBER

1. Hypodontia
2. Hyperdontia

SIZE

1. Microdontia
2. Macrodontia

SHAPE

1. Gemination
2. Fusion
3. Concrescence
4. Accessory cusps
5. Dens invaginatus
6. Ectopic enamel
7. Taurodontism
8. Hypercementosis
9. Accessory roots
10. Dilaceration

Developmental Alterations in the Number of Teeth

Complete anodontia is rare but is often associated with a syndrome known as *hereditary ectodermal dysplasa*

- **Partial anodontia** , few teeth that are present are usually conical.

Hereditary ectodermal dysplasia resulting in lack of hair (including eyebrows and eyelashes) and poorly developed sweat glands.

Anodontia of a permanent second premolar with ankylosis of an erupted primary molar.

Mesiodens.

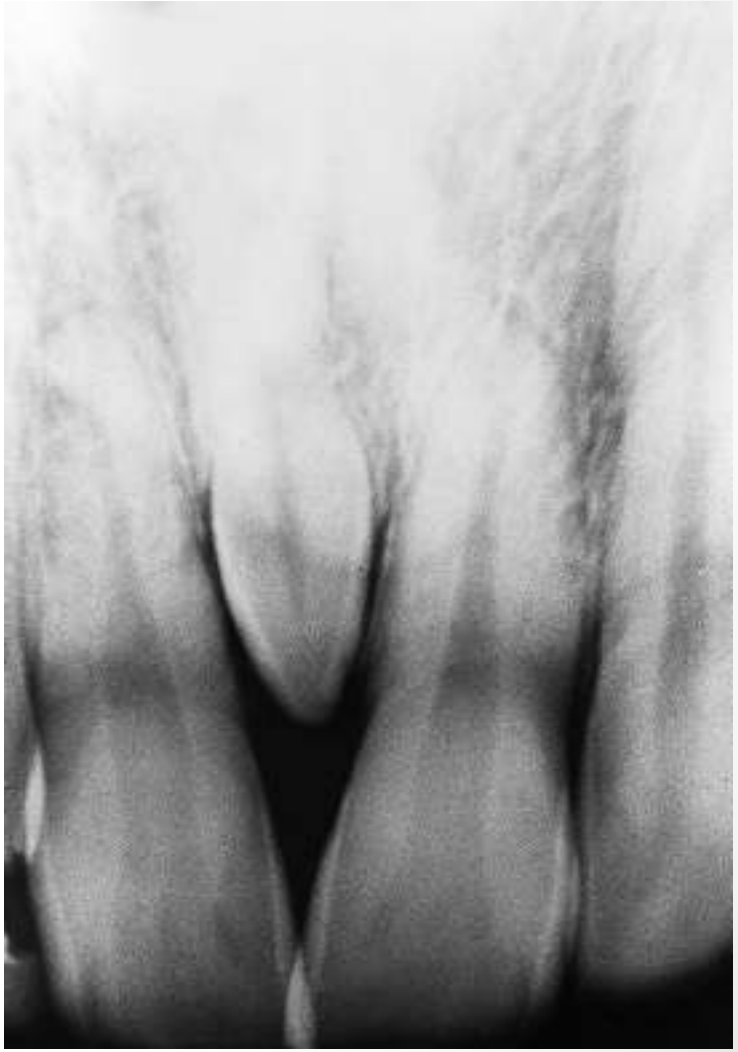

Mesiodens erupted.

Figure 2-49 • Natal teeth. Mandibular central incisors that were erupted at birth.

Supernumerary premolar.

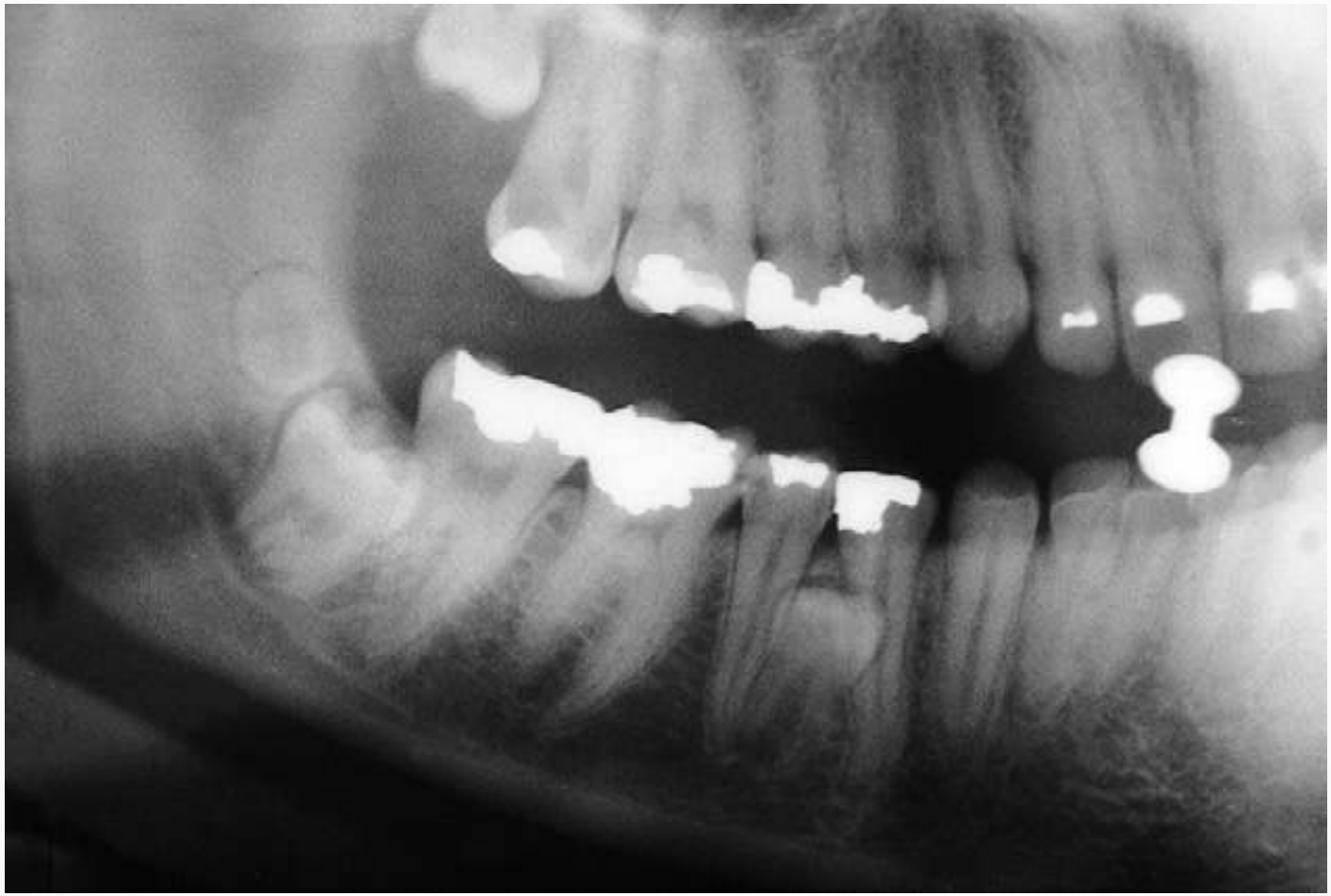

Developmental Alterations in the Size of Teeth

Figure 2-50 • **Diffuse microdontia.** Dentition in which the teeth are smaller than normal and widely spaced within the arch.

Microdont.

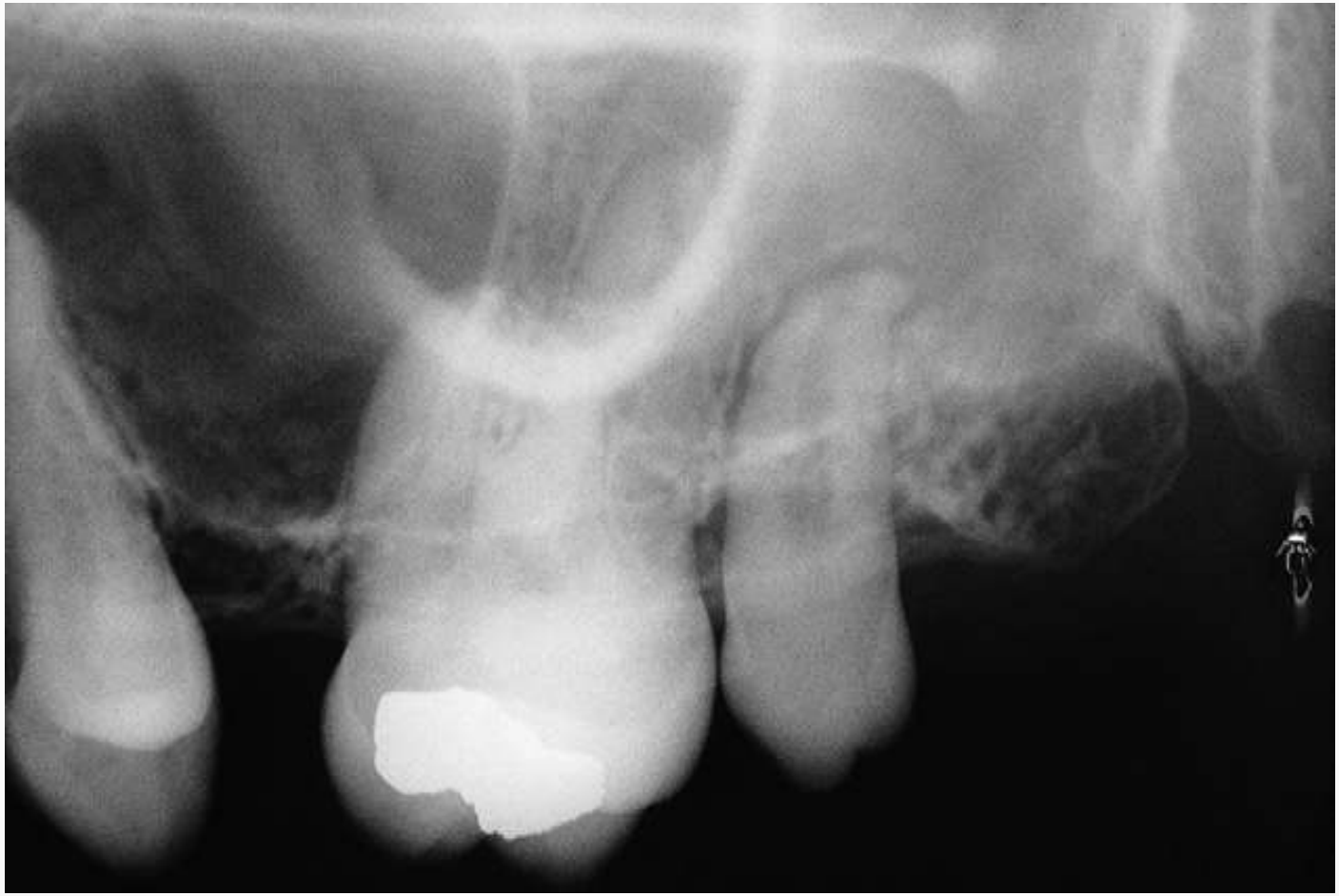

Figure 2-51 • Isolated microdontia (peg lateral). Small, cone-shaped right maxillary lateral incisor.

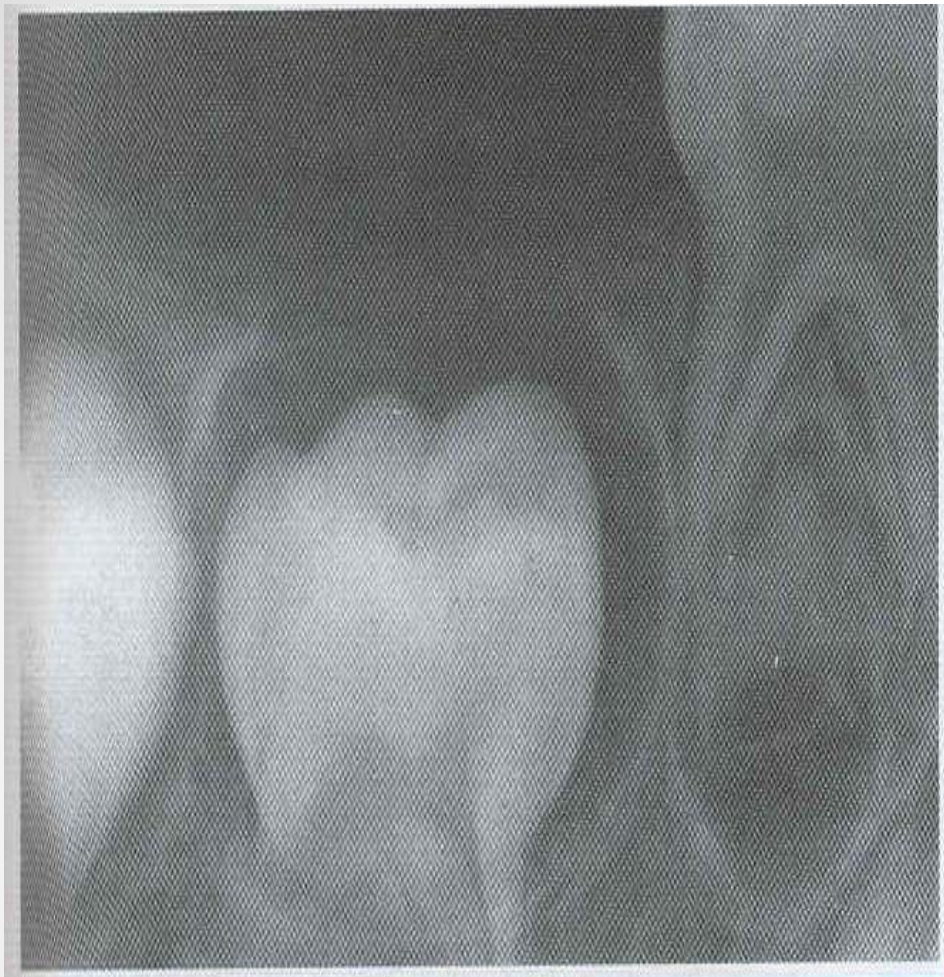

Figure 2-36 • Primary impaction of deciduous tooth. The right secondary primary molar demonstrates delayed eruption and enlarged pericoronal radiolucency. (Courtesy of Dr. G. Thomas Kluemper.)

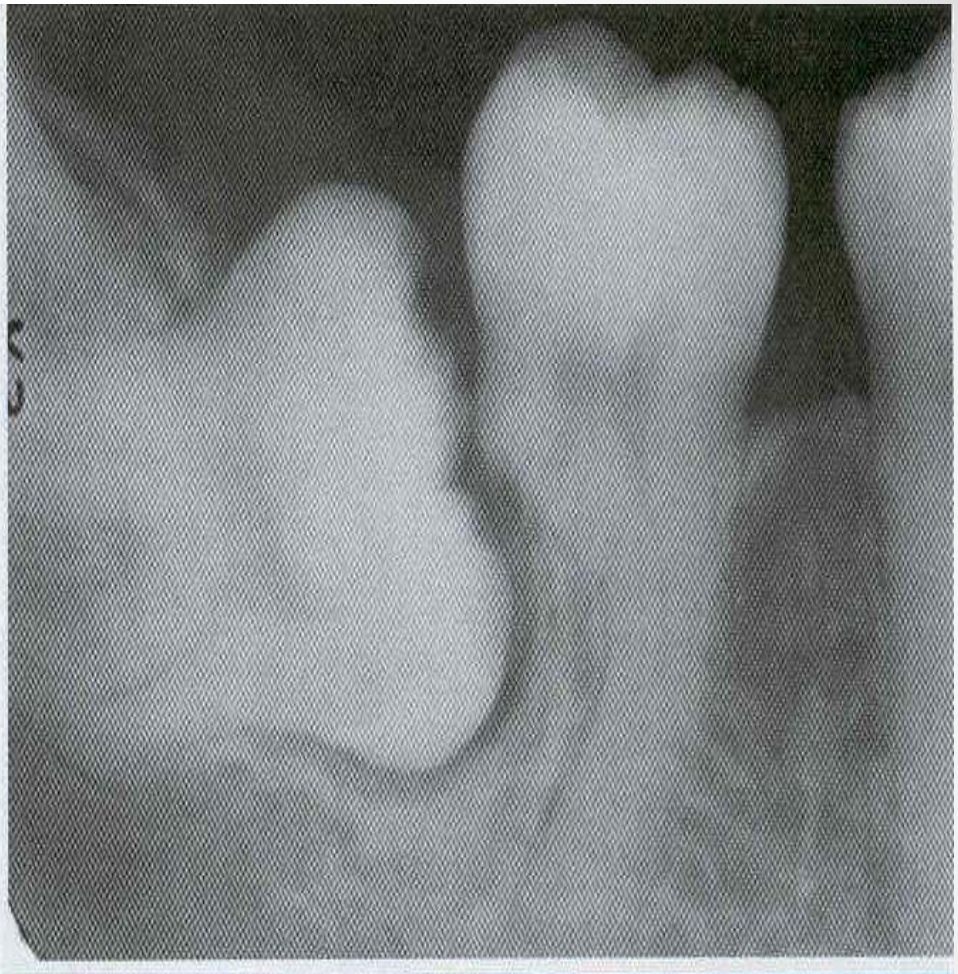

Figure 2-37 • Impaction-related tooth resorption. Mesioangular impaction of the right mandibular third molar associated with significant resorption of the distal root of the second molar. (Courtesy of Dr. Richard Brock.)

Ankylosis,.

- The reason for ankylosis is unknown, but it is believed to be related to periapical inflammation and subsequent bone repair.
- With focal loss of the periodontal ligament, bone and cementum become mixed, causing fusion of the tooth to alveolar bone.

1-Gemination

It is the fusion of two teeth from a **single enamel organ**. The typical result is **partial cleavage**, with the appearance of two crowns that share the same root canal.

Complete cleavage, or twinning, occasionally occurs, resulting in two teeth from one tooth germ.

Although **trauma** has been suggested as a possible cause, the cause of gemination is unknown.

These teeth may be cosmetically unacceptable and may cause **crowding**..

Figure 2-53 • **Gemination.** Mandibular bicuspid exhibiting bifid

Figure 2-52 • **Bilateral gemination.** Two double teeth. The tooth count was normal when each anomalous tooth was counted as one.

Gemination.

Fusion.

Figure 2-55 • **Fusion.** Double tooth in the place of the mandibular right lateral incisor and cuspid.

Fusion.

Figure 2-59 • **Concrescence.** Union by cementum of adjacent maxillary molars.

Concrescence

Clinical and Radiographic Features *(ACCESSORY CUSPS)*

1-The cusp of Carabelli.

2-Talon cusp **A talon cusp (dens evaginatus of anterior tooth)** is a well-delineated additional cusp that is located on the surface of an anterior tooth.

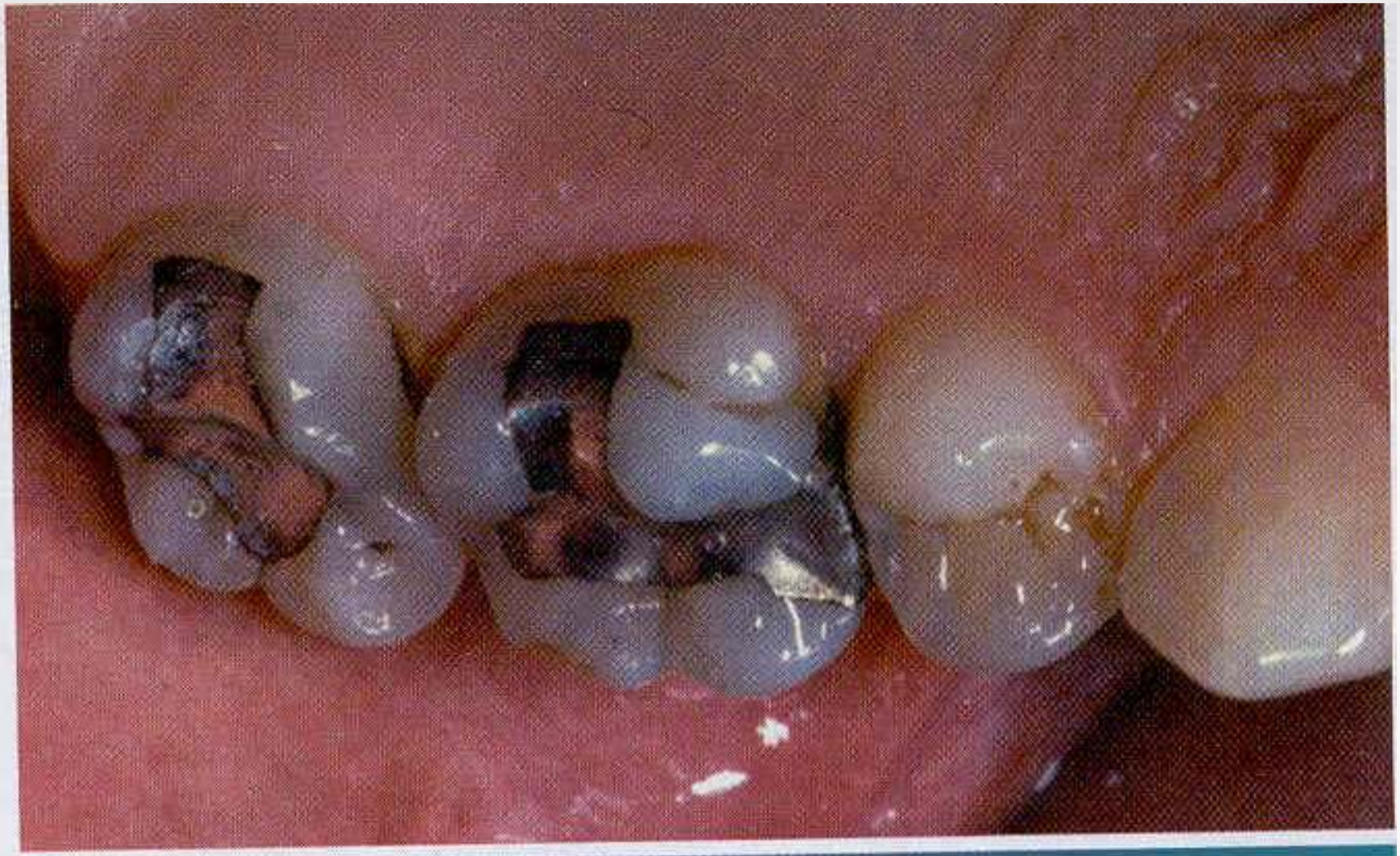

Figure 2-62 ◆ **Cusp of Carabelli.** Accessory cusp on the mesiolingual surface of the maxillary first molar.

Figure 2-63 • **Talon cusp.** Accessory cusp present on the palatal surface of the maxillary left central incisor. Note the three-pronged pattern, which resembles an eagle talon.

Odontoma like lesions:

1-Dens Invaginatus : Also known as **dens in dente** or tooth within a tooth arises as a result of **invagination** of a portion of enamel organ into the dental papilla at an early stage in odontogenesis before the formation of calcified tissue.

Dens invaginatus of lateral incisors.

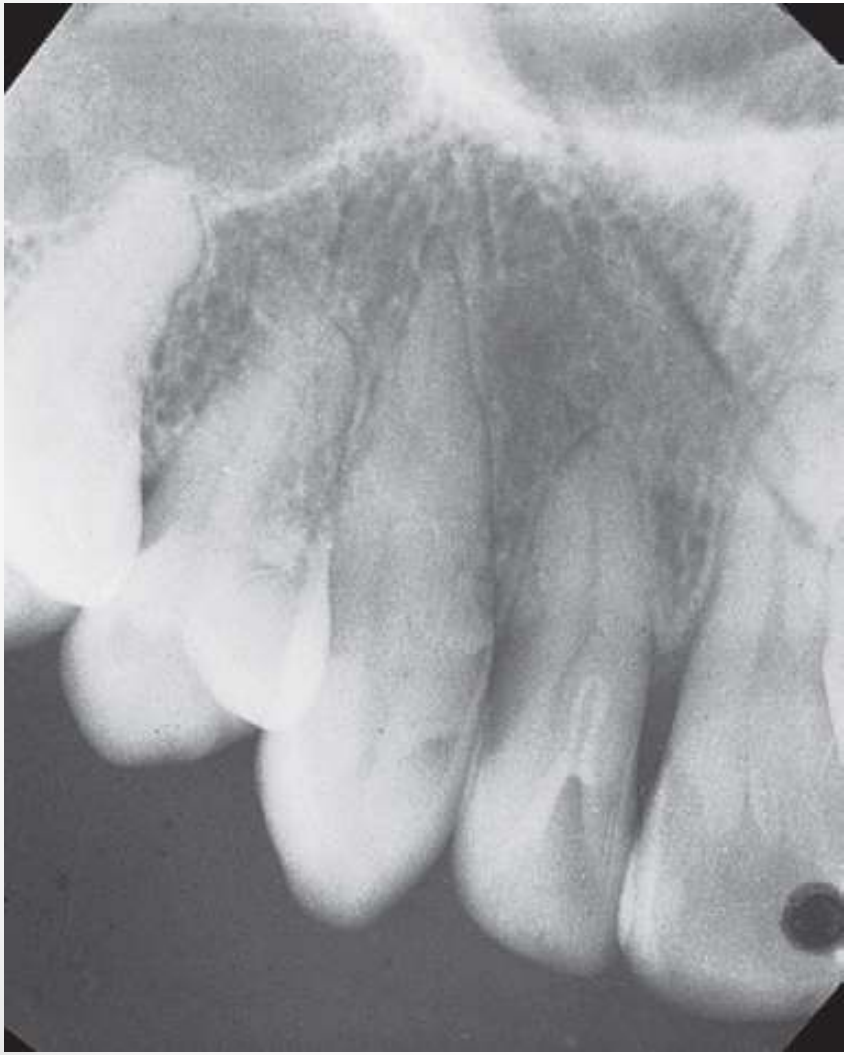

2-Dens Evaginatus :- is a relatively common developmental condition affecting predominantly premolar teeth .

The defect, which is often bilateral, is an anomalous **tubercle, or cusp**, located at the center of the occlusal surface.

Because of occlusal abrasion, the tubercle wears relatively quickly causing **early exposure of an accessory pulp horn that extends into the tubercle.**

Morphology of dens invaginatus and dens evaginatus

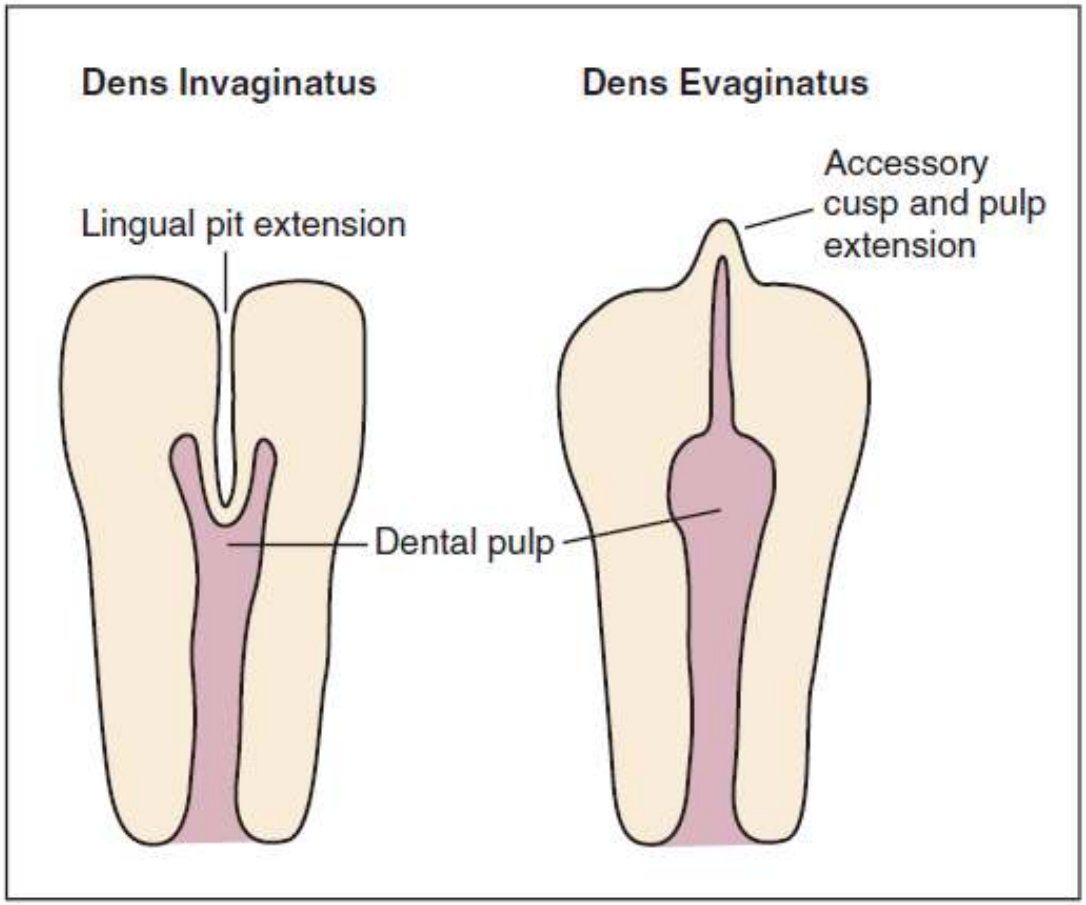

Dens evaginatus of mandibular second premolars.

Dens evaginatus with associated periapical lesions.

Enamel pearl.

Taurodontism

Taurodontism is a variation in tooth form in which teeth have **elongated crowns** or apically displaced furcations, resulting in pulp chambers that have **increased apical-occlusal height.**

Taurodontism

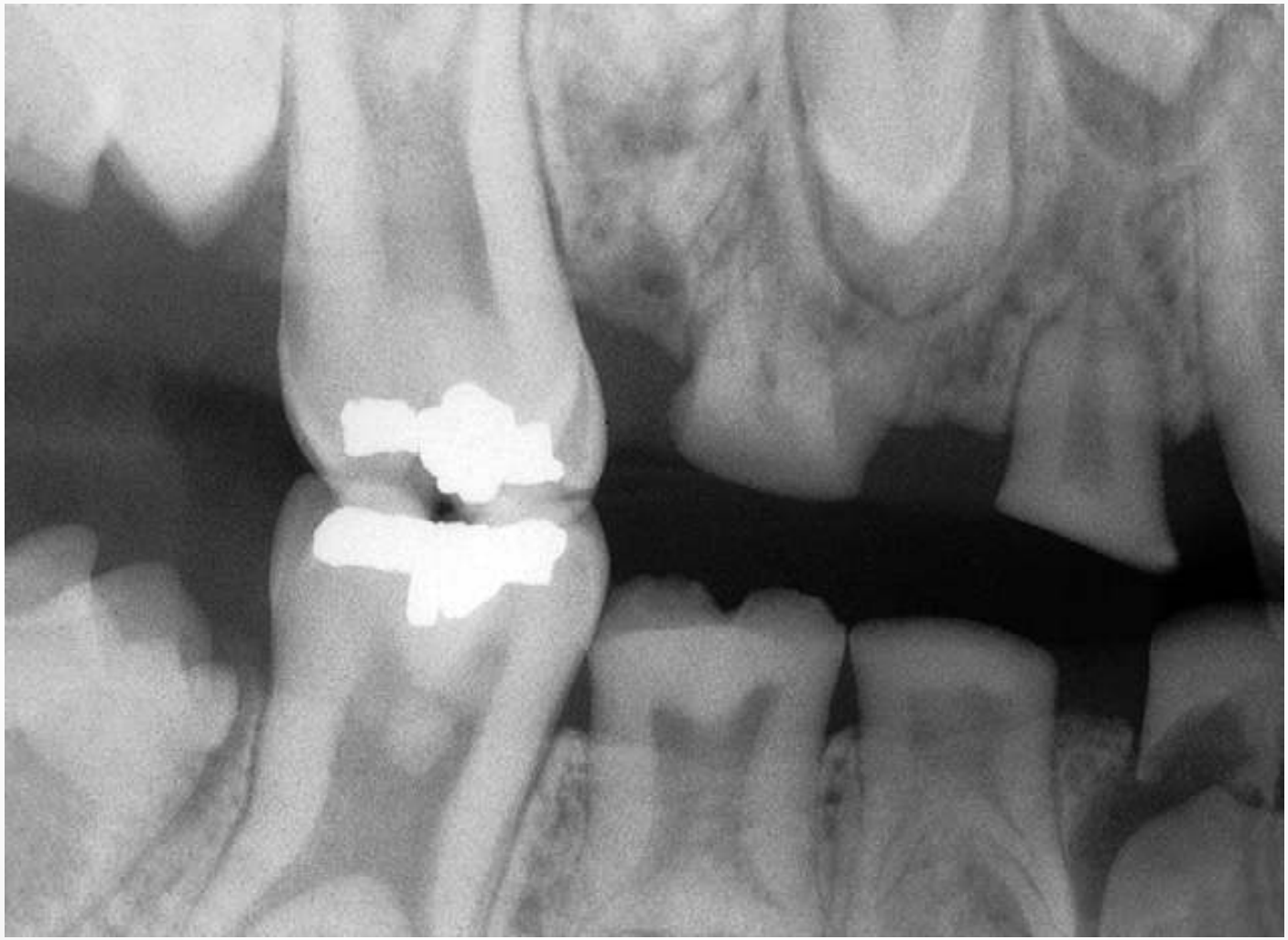

Dilaceration.

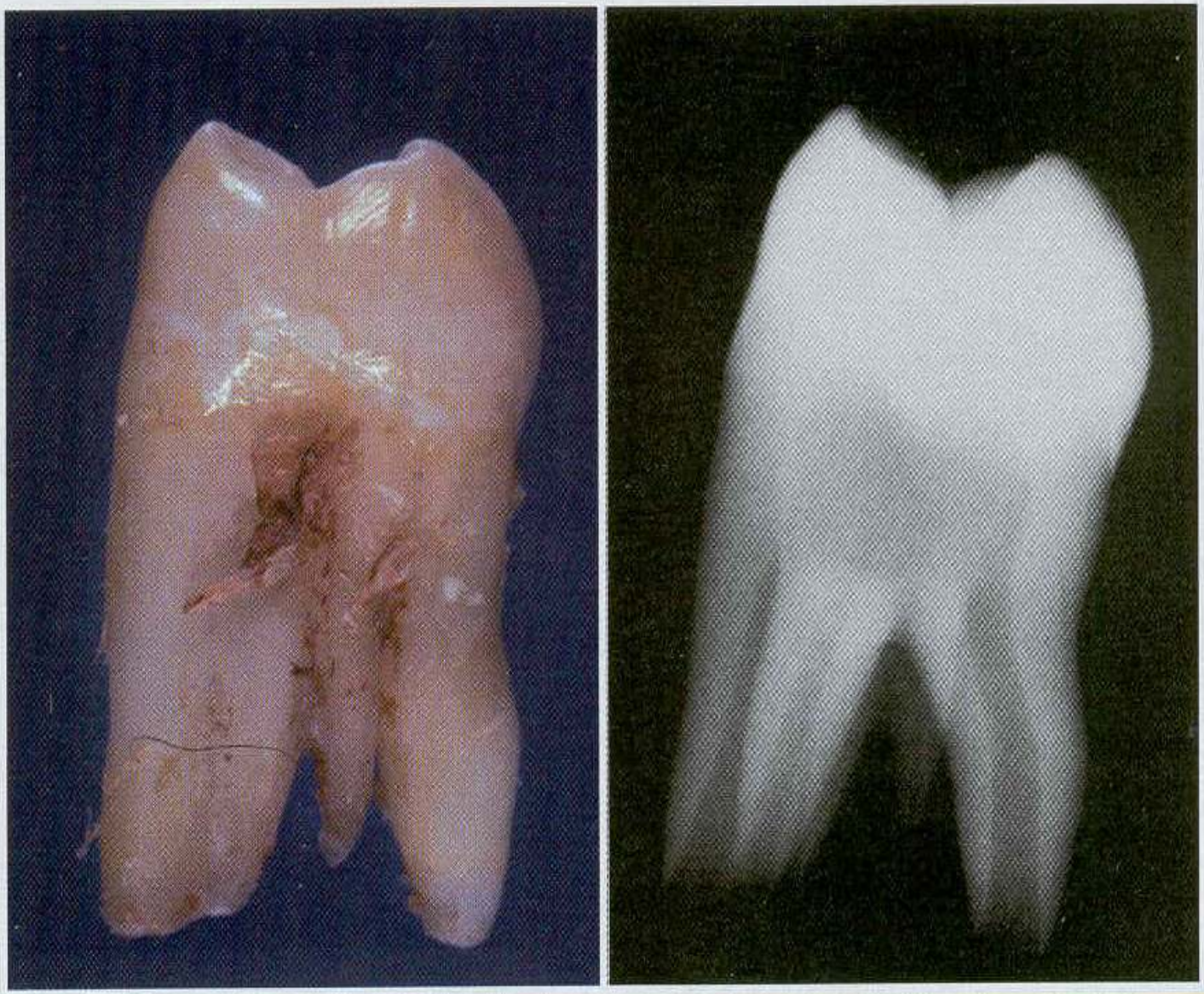

Figure 2-87 • Supernumerary root. A, Gross photograph exhibiting a maxillary molar with a small supernumerary root. **B,** Mesial-to-distal radiographic view exhibiting the accessory root with central pulp canal. If a buccal-to-lingual radiographic view had been taken (as would be necessary in patient care), the additional root would not have been evident.

Environmental alteration of teeth

- **hypoplastic type of amelogenesis imperfecta,** teeth erupt with **insufficient amounts of enamel**, abnormal contour and absent interproximal contact points may be evident.
- **hypocalcified type,** the quantity of enamel is normal, but it is **soft and friable**, so that it fractures and wears readily.

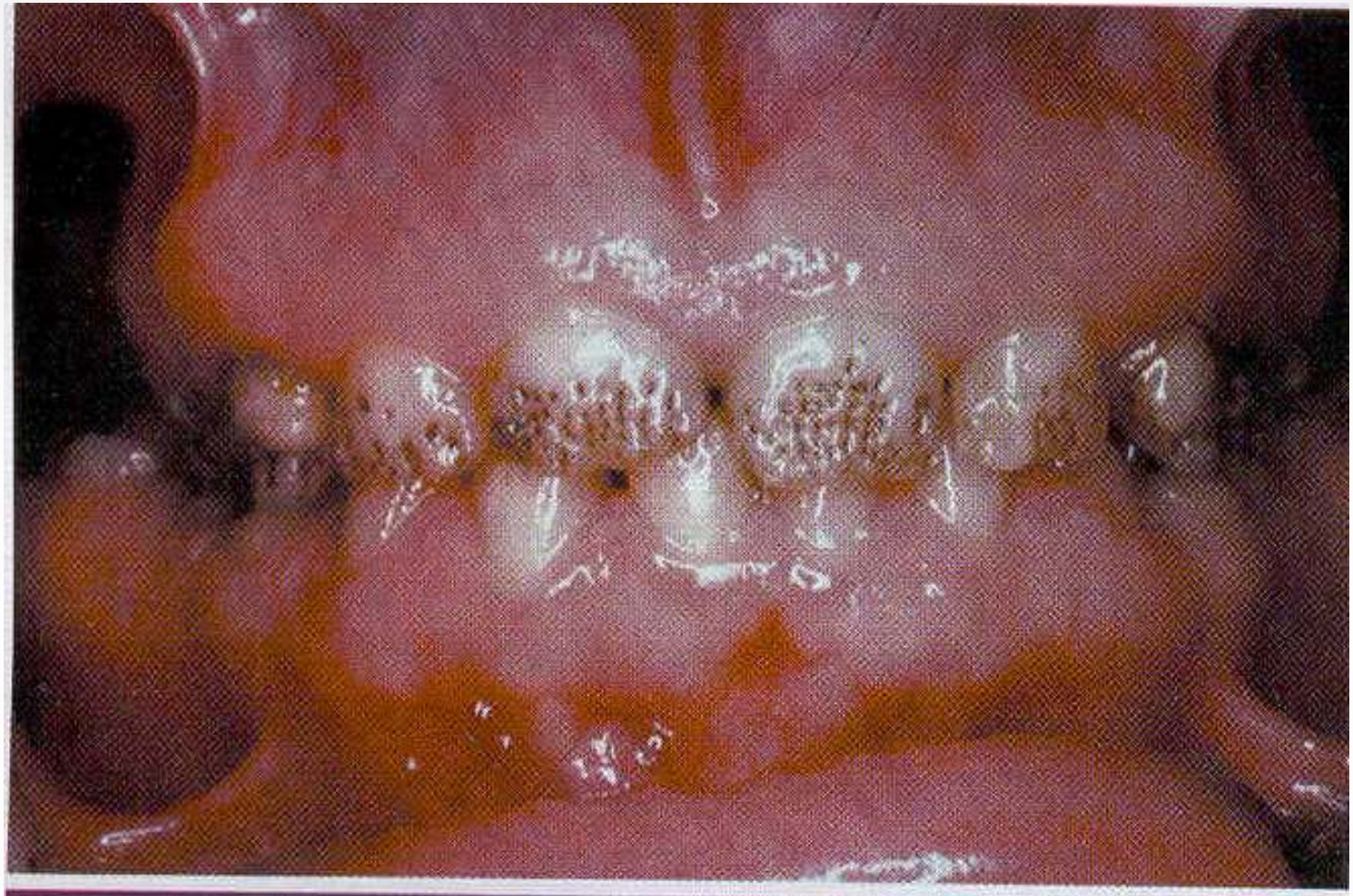

Figure 2-89 • Hypoplastic amelogenesis imperfecta, generalized pitted pattern. Note the numerous pinpoint pits scattered across the surface of the teeth. The enamel between the pits is of normal thickness, hardness, and coloration. (From Stewart RE, Prescott GH: *Oral facial genetics*, St Louis, 1976, Mosby.)

Figure 2-95 • Hypomaturation amelogenesis imperfecta.
Dentition exhibiting mottled, opaque white enamel with scattered areas of brown discoloration.

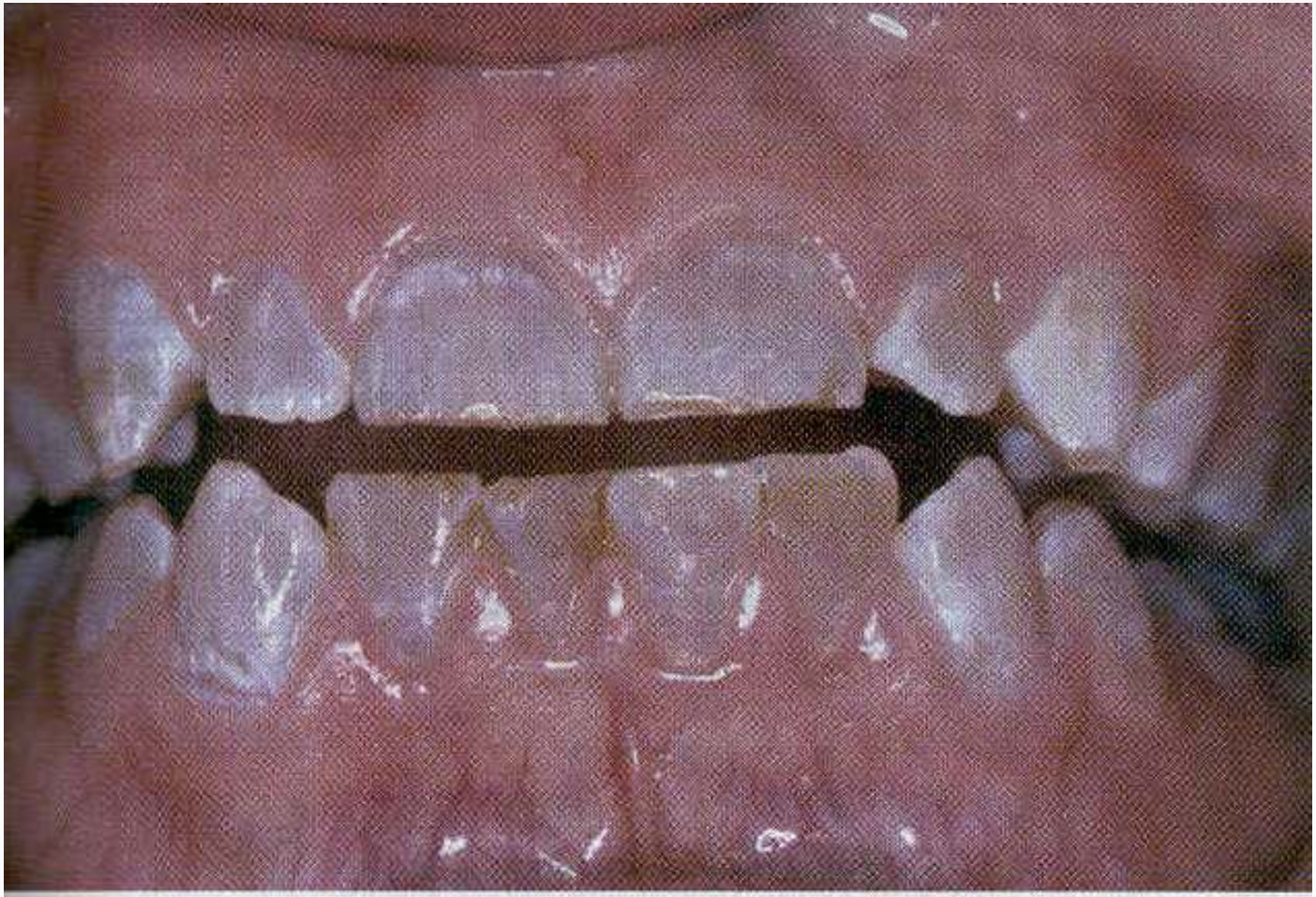

Figure 2-101 • **Dentinogenesis imperfecta.** Dentition exhibiting diffuse brownish discoloration and slight translucence.

Radiographically (D.I)

types I and II exhibit identical changes.

- **Opacification** of dental pulps occurs as the result of continued deposition of abnormal dentin.
- The **short roots** and the **bell-shaped crowns** .

In type III, the dentin appears **thin** and the pulp chambers and root canals extremely **large**, giving the appearance of thin dentin shells—hence the previous designation of ***shell teeth***.

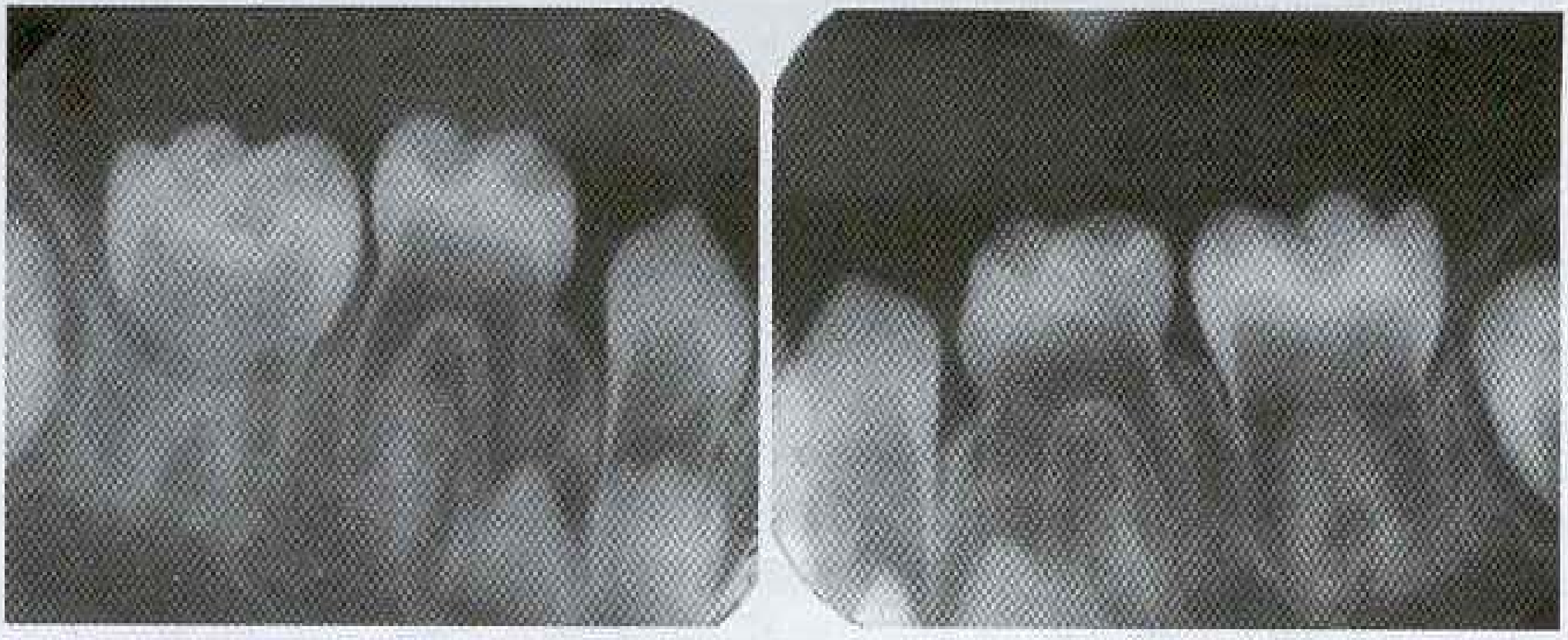

Figure 2-105 ◆ Shell teeth. Dentition exhibiting normal thickness enamel, extremely thin dentin, and dramatically enlarged pulps.

Microscopically

- the dentin of teeth in dentinogenesis imperfecta contains **fewer, but larger** and irregular, dentinal tubules.
- The pulpal space is nearly completely replaced over time by irregular dentin.
- Enamel appears normal, but the dentinoenamel junction is **smooth** instead of scalloped.

Dentin Dysplasia

- In dentin dysplasia type II, the color of the primary dentition is opalescent and the permanent dentition is normal.
- The coronal pulps in type II are usually large and are filled with globules of abnormal dentin.

- in type I, both dentitions are of normal color.

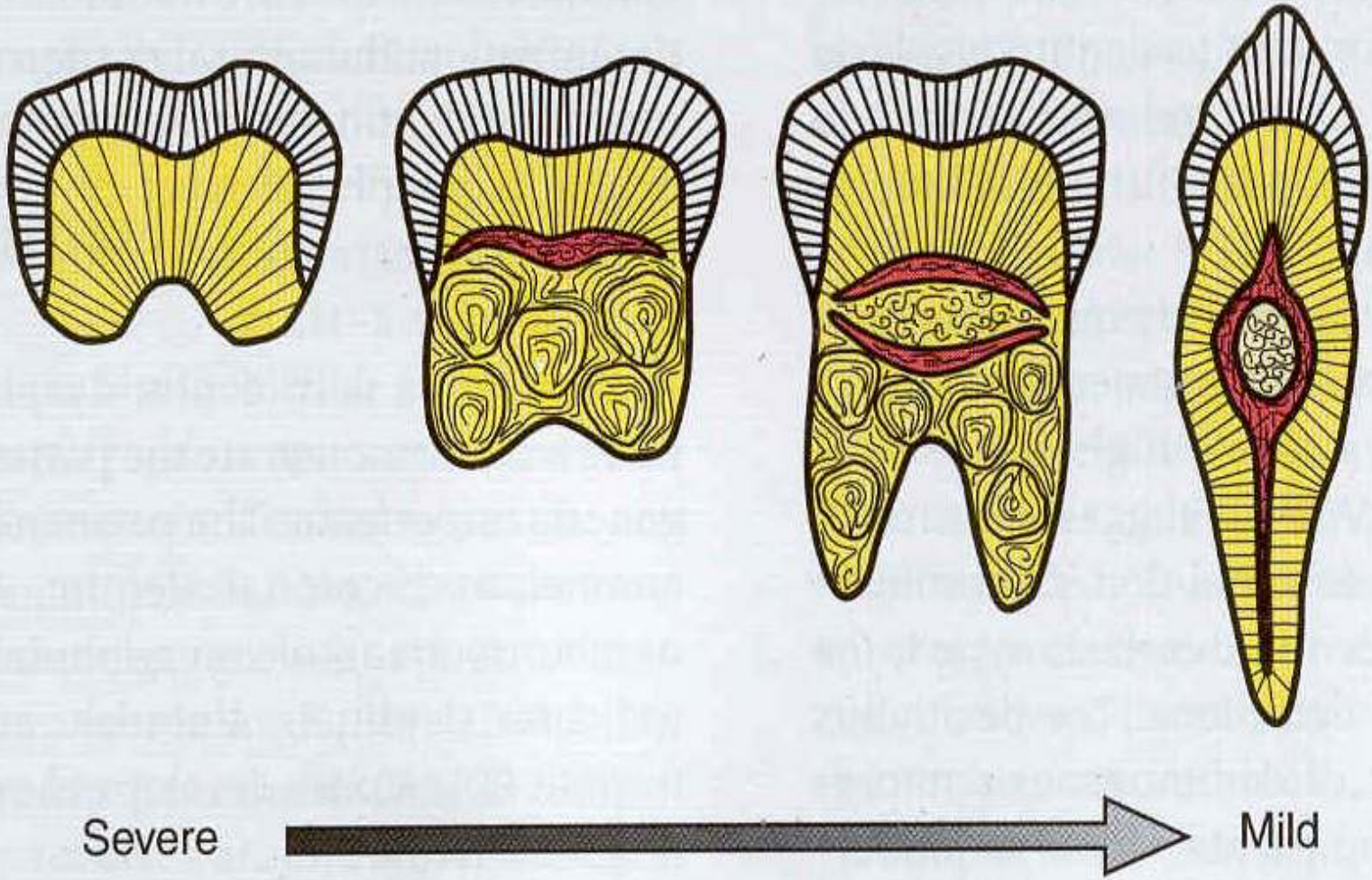

Figure 2-109 • Dentin dysplasia type I. Illustration demonstrating the variability of the radiographic appearance according to the degree of dentin disorganization within the root.

Radiographically dentin dysplasia

- in dentin dysplasia type I, roots appear extremely **short** and pulps are almost completely obliterated.
- Residual fragments of pulp tissue appear typically as horizontal lucencies (**chevrons**).
- **Periapical lucencies** are typically seen; they represent chronic abscesses, granulomas, or cysts.
- In dentin dysplasia type II, permanent teeth exhibit enlarged pulp chambers that have been described as **thistle tube** in appearance.

Figure 2-111 ◆ **Dentin dysplasia type II.** Radiographic appearance of the dentition depicted in Figure 2-110. Note thistle tube-shaped enlargements of the pulp chambers and numerous pulp stones.

Figure 2-107 • **Dentin dysplasia type I.** Dentition exhibiting attrition but otherwise normal coronal coloration and morphology.

Figure 2-108 • **Dentin dysplasia type I.** Dentition exhibiting shortened roots, no pulp canals, and small crescent-shaped pulp chambers. (From Tidwell E, Cunningham CJ: Dentinal dysplasia. Endodontic treatment, with case report, *J Endod* 5:372-376, 1979.)

Microscopically

- the enamel and the immediately subjacent dentin appear normal.
- Deeper layers of dentin show **atypical tubular patterns, with amorphous, atubular areas and irregular organization.**
- On the pulpal side of the normal-appearing mantle of dentin, globular or nodular masses of abnormal dentin are seen.

Treatment

is directed toward retention of teeth for as long as possible.

However, because of the short roots and periapical lesions, the prognosis for prolonged retention is poor.

DEFECTS OF ENAMEL AND DENTIN

Regional Odontodysplasia

- Regional odontodysplasia is a dental abnormality that involves the hard tissues derived from both epithelial (enamel) and mesenchymal (dentin and cementum) components of the tooth-forming apparatus.
- The maxilla or mandible are affected to the extent that they exhibit <u>short roots, open apical foramina, and enlarged pulp chambers.</u>

- The thinness and poor mineralization quality of the enamel and dentin layers have given rise to the term **ghost teeth**.
- The permanent teeth are more affected than the primary teeth
- the maxillary anterior teeth are more affected than other teeth.
- Eruption of the affected teeth is delayed

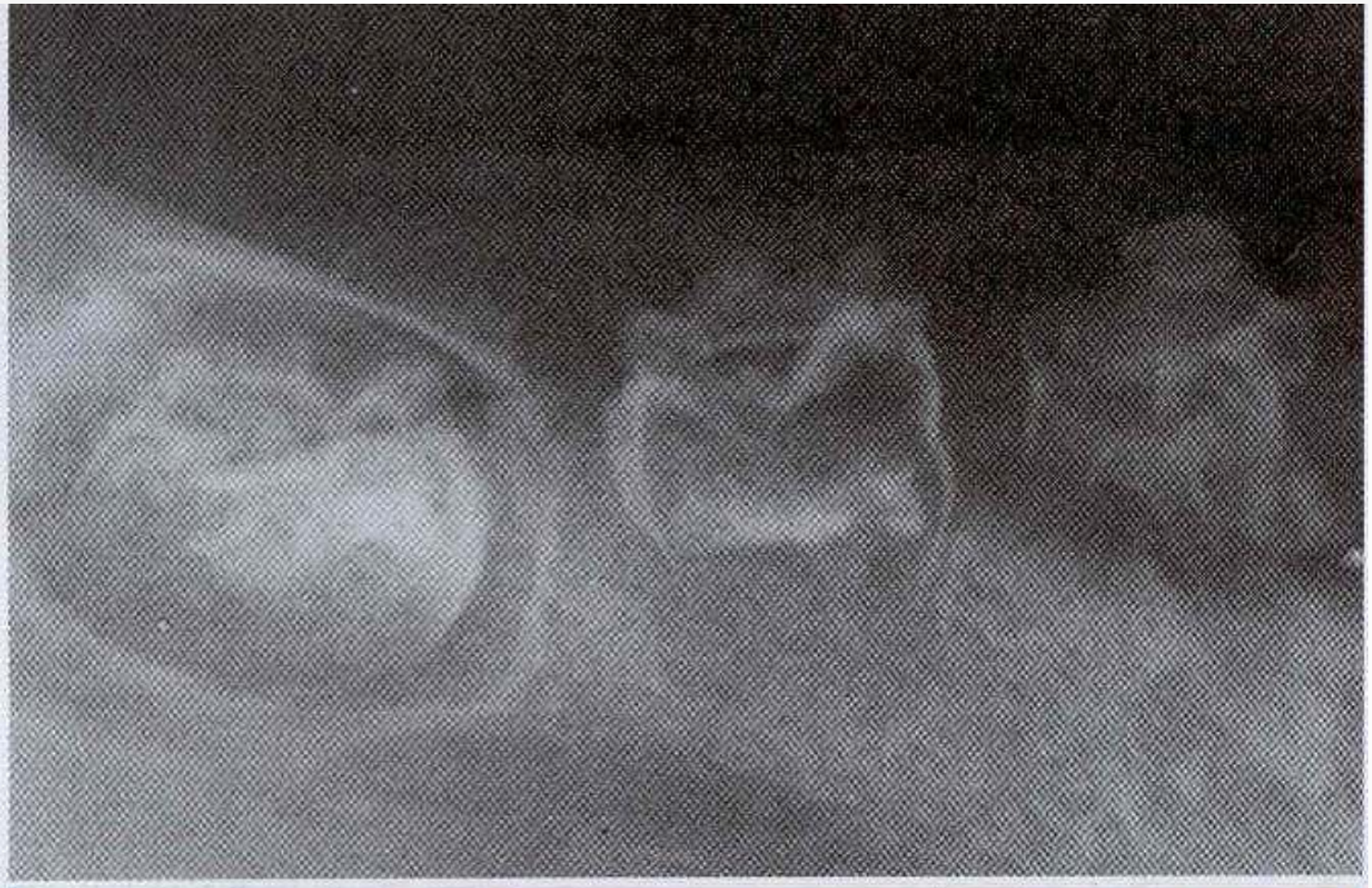

Figure 2-114 • Regional odontodysplasia (ghost teeth). Posterior mandibular dentition exhibiting enlarged pulps and extremely thin enamel and dentin. (Courtesy of Dr. John B. Perry.)

ENVIRONMENTAL EFFECTS ON TOOTH STRUCTURE DEVELOPMENT

DEFECTS OF ENAMEL Environmental Defects of Enamel

Metabolic injury, if severe enough and long enough, can cause defects in the quantity and shape of enamel or in the quality and color of enamel.

- **Quantitatively** defective enamel, when of normal hardness, is known as ***enamel hypoplasia***.
- **Qualitatively** defective enamel, in which normal amounts of enamel are produced but are hypomineralized, is known as ***enamel hypocalcification***. In this defect, the enamel is **softer** than normal.

Figure 2-1 • **Environmental enamel hypoplasia.** Bilaterally symmetric pattern of horizontal enamel hypoplasia of the anterior dentition. Maxillary central incisors have been restored previously. (From Neville BW, Damm DD, White DK: *Color atlas of clinical oral pathology,* ed 2, Baltimore, 1999, Williams & Wilkins.)

Figure 2-2 • **Environmental enamel hypoplasia.** Same patient as depicted in Figure 2-1. Note the lack of enamel damage on bicuspids. (From Neville BW, Damm DD, White DK: *Color atlas of clinical oral pathology,* ed 2, Baltimore, 1999, Williams & Wilkins.)

The extent of the enamel defect is dependent on three conditions:

(1) the **intensity** of the causative factor.

(2) the **duration** of the factor's presence.

(3) the **time** at which the factor occurs during crown development.

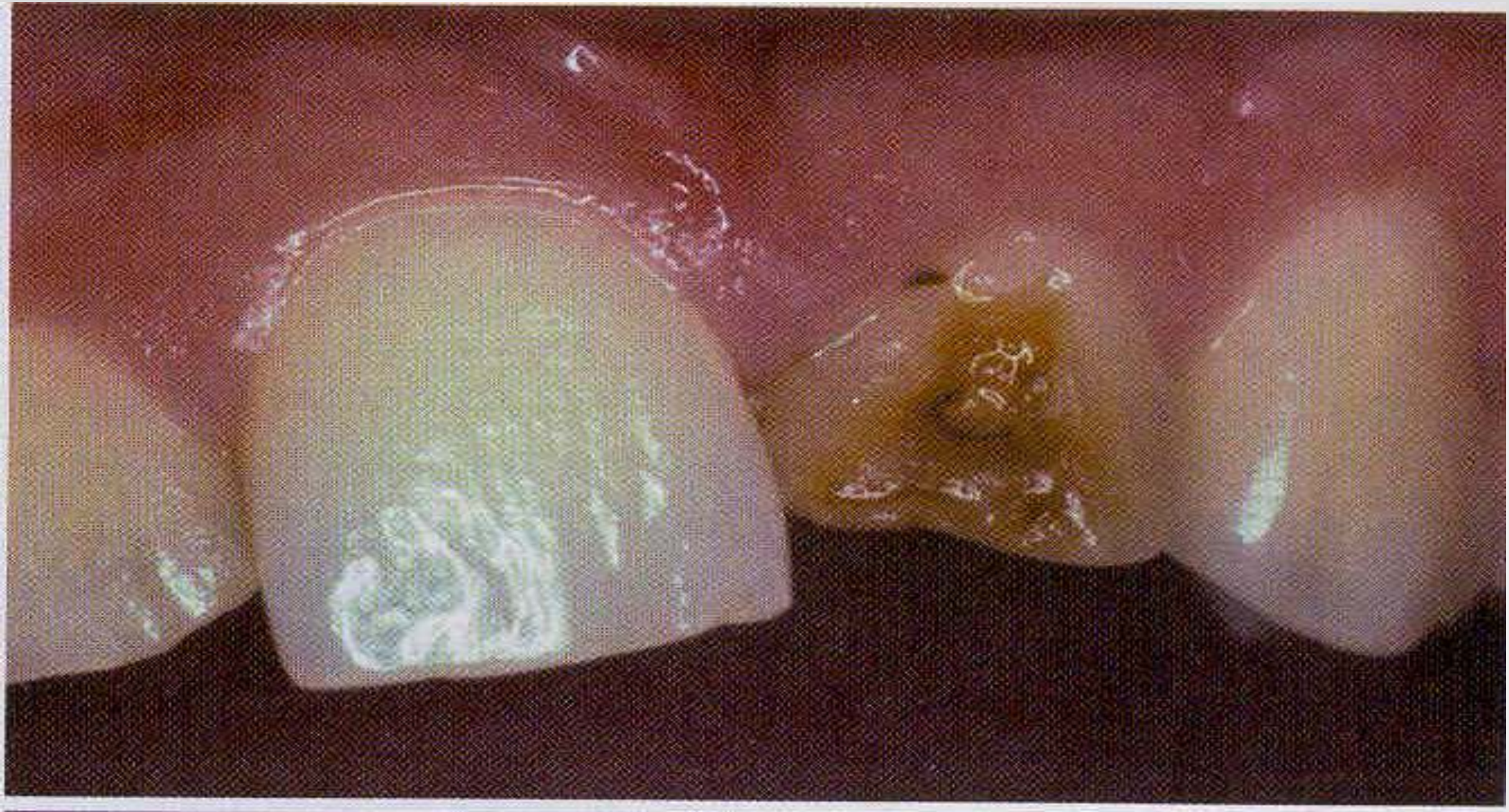

Figure 2-6 ◆ Turner's hypoplasia. Extensive coronal hypoplasia of permanent maxillary left central incisor secondary to previous trauma to deciduous central incisor.

Figure 2-8 • Dental fluorosis. Dentition exhibiting lusterless, white, and opaque enamel.

Syphilitic hypoplasia..

- Anterior teeth altered by syphilis are termed **Hutchinson's incisors** and exhibit crowns that are shaped like straight-edge screw drivers.
- Altered posterior teeth are termed **mulberry molars** .

Figure 5-11 • Hutchinson's incisors of congenital syphilis. Dentition exhibiting crowns tapering toward the incisal edges. (From Halstead CL, Blozis GG, Drinnan AJ, Gier RE: *Physical evaluation of the dental patient*, St Louis, 1982, Mosby.)

Figure 5-12 • Mulberry molar of congenital syphilis. Maxillary molar demonstrating occlusal surface with numerous globular projections.

Post developmental Loss of Tooth

Attrition, Abrasion, Erosion and Abfraction

Attrition is the physiologic wearing of teeth as a result of mastication. It is an age-related process

Figure 2-10 • Attrition. Extensive loss of coronal tooth height without pulp exposure in patient with anterior edge-to-edge occlusion.

Figure 2-19 • **Abfraction.** Deep and narrow enamel cervical defects on the facial surface of the mandibular dentition. (From Neville BW, Damm DD, White DK: *Color atlas of clinical oral pathology*, ed 2, Baltimore, 1999, Williams & Wilkins.)

Internal and External Resorption

Internal Resorption

Resorption of the dentin of the pulpal walls may be seen as part of an inflammatory response to pulpal injury.

The resorption occurs as a result of activation of **osteoclasts or dentinoclasts** on internal surfaces of the root or crown.

Figure 2-21 • **Internal resorption** (pink tooth of Mummery). Pink discoloration of the maxillary central incisor.

Figure 2-22 • Internal resorption. Same patient as depicted in Figure 2-21. Note extensive resorption of both maxillary central incisors.

External Resorption

This change may be the result of an adjacent pathologic process, such as

(1) chronic inflammatory lesions.

(2) cysts.

(3) benign tumors.

(4) malignant neoplasms.

External resorption of teeth may also be seen in association with

(1) trauma.

(2) Re implantation or transplantation of teeth.

(3) impaction.

Figure 2-24 • External resorption. Extensive irregular destruction of both roots of the mandibular second molar associated with chronic periodontitis. (Courtesy of Dr. Tommy Shimer.)

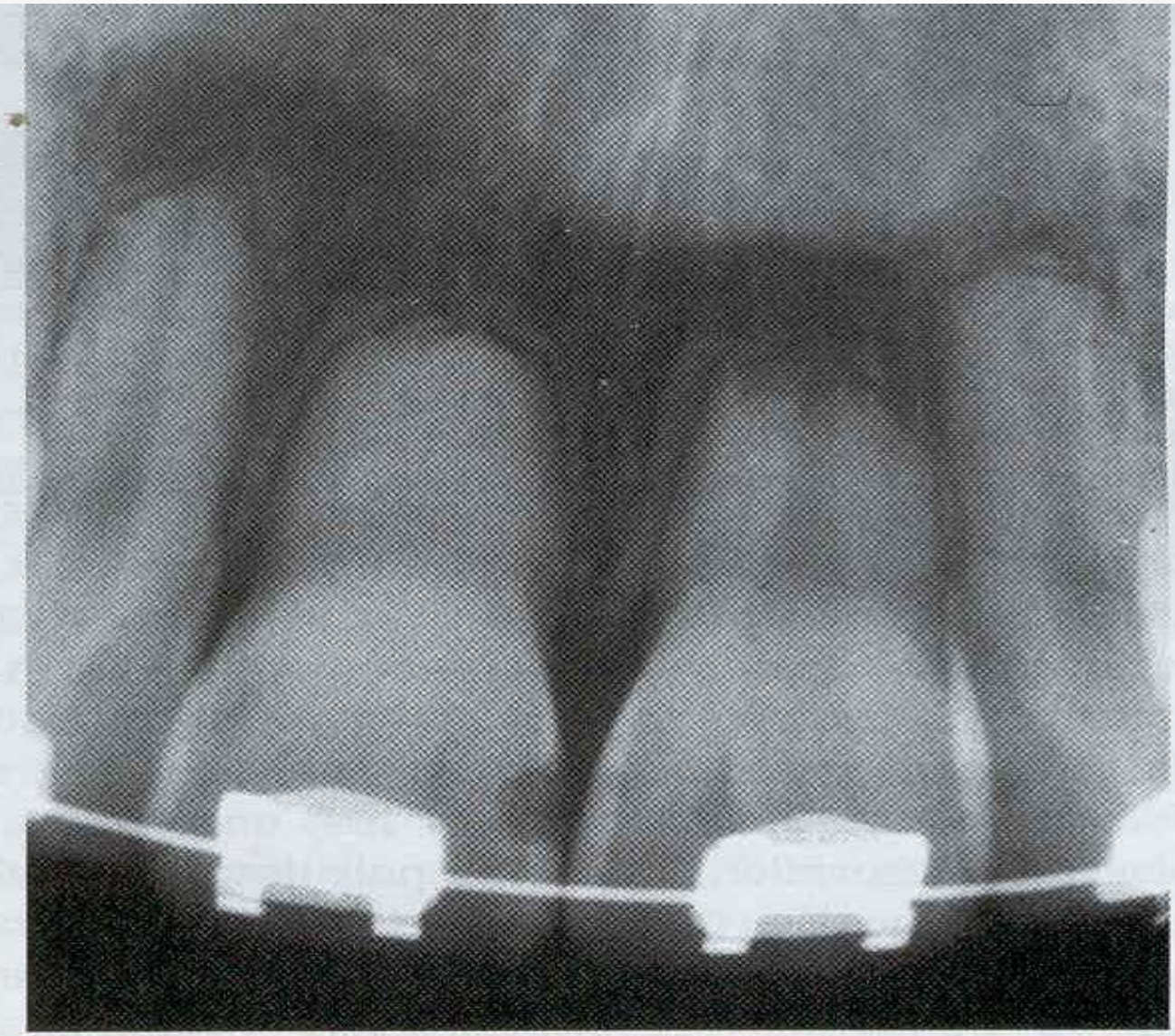

Figure 2-27 ◆ External resorption. Diffuse external resorption of radicular dentin of maxillary dentition. This process arose after initiation of orthodontics.

Figure 2-31 • Amalgam discoloration. Greenish-gray discoloration of mandibular central incisor, which had endodontic access preparation restored with amalgam.